



# diabetic retinopathy

a closer look

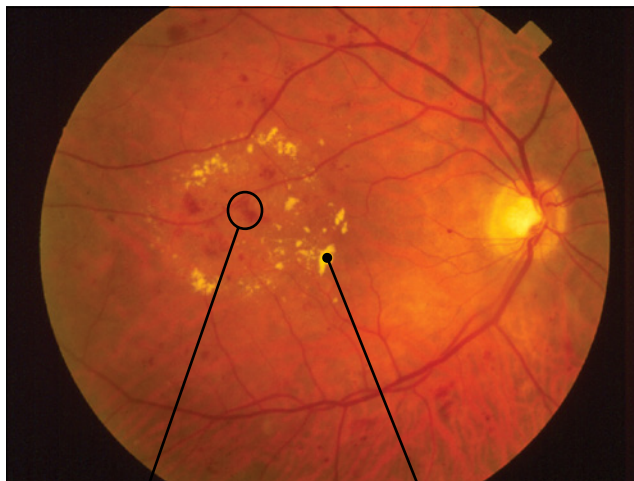## DIABETES CAN AFFECT SIGHT

If you have diabetes mellitus, your body does not use and store sugar properly. High blood sugar levels can damage blood vessels in the retina, the nerve layer at the back of the eye that senses light and helps to send images to the brain. The damage to retinal vessels is referred to as diabetic retinopathy.

## TYPES OF DIABETIC RETINOPATHY

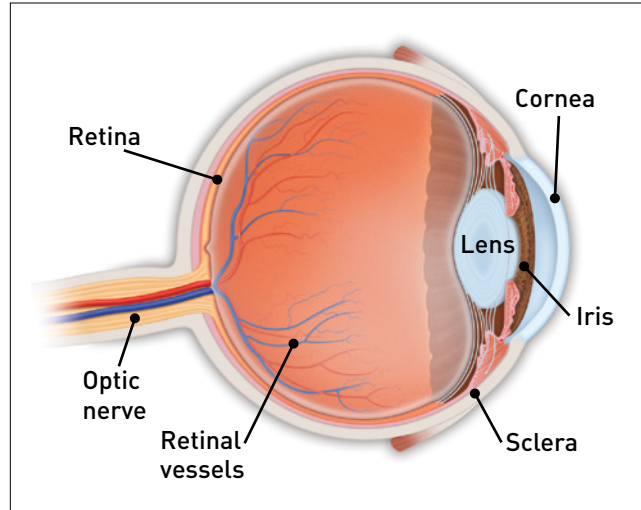
There are two types of diabetic retinopathy:  
**nonproliferative diabetic retinopathy (NPDR)**  
and **proliferative diabetic retinopathy (PDR)**.

**NPDR**, commonly known as **background retinopathy**, is an early stage of diabetic retinopathy. In this stage, tiny blood vessels within the retina leak blood or fluid. The leaking fluid causes the retina to swell or to form deposits called **exudates**.



Retinal hemorrhages

Hard exudates



Many people with diabetes have mild NPDR, which usually does not affect their vision. When vision is affected it is the result of **macular edema** (pronounced eh-DEEM-uh), **macular ischemia** (pronounced ih-SKEE-mee-uh), or both.

- Macular edema is swelling or thickening of the macula, a small area in the center of the retina that allows us to see fine details clearly. The swelling is caused by fluid leaking from retinal blood vessels. It is the most common cause of visual loss in diabetes. Vision loss may be mild to severe, but even in the worst cases, peripheral vision continues to function.
- Macular ischemia occurs when small blood vessels (capillaries) close. Vision blurs because the macula no longer receives sufficient blood supply to work properly.

**PDR** is present when abnormal new vessels (**neovascularization**) begin growing on the surface of the retina or optic nerve. The main cause of PDR is widespread closure of retinal blood vessels, preventing adequate blood flow. The retina responds by growing new blood vessels in an attempt to supply blood to the area where the original vessels closed.

Unfortunately, the new abnormal blood vessels do not resupply the retina with normal blood flow. The new vessels are often accompanied by scar tissue that may cause wrinkling or detachment of the retina.

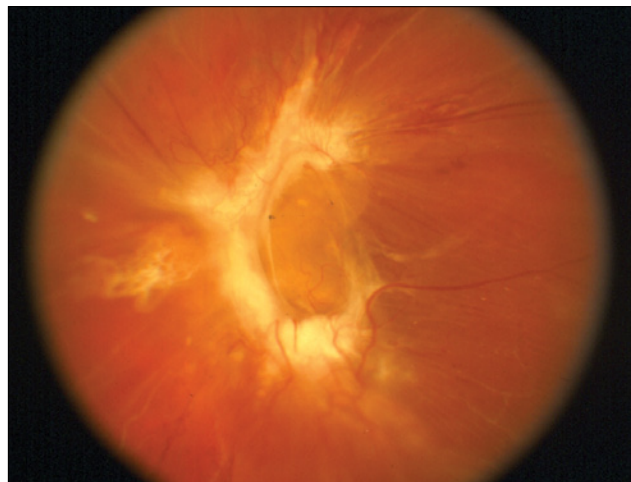PDR may cause more severe vision loss than NPDR because it can affect both central and peripheral vision.

Proliferative diabetic retinopathy causes visual loss in the following ways:

**Vitreous hemorrhage.** The fragile new vessels may bleed into the vitreous, a clear, gel-like substance that fills the center of the eye. If the vitreous hemorrhage is small, a person might see only a few new, dark floaters. A very large hemorrhage might block out all vision.

It may take days, months or even years to reabsorb the blood, depending on the amount of blood present. If the eye does not clear the vitreous blood adequately within a reasonable time, vitrectomy surgery may be recommended.

Vitreous hemorrhage alone does not cause permanent vision loss. When the blood clears, vision may return to its former level unless the macula is damaged.



**Traction retinal detachment**

**Traction retinal detachment.** When PDR is present, scar tissue associated with neovascularization can shrink, wrinkling and pulling the retina from its normal position. Macular wrinkling can cause visual distortion. More severe vision loss can occur if the macula or large areas of the retina are detached.

**Neovascular glaucoma.** Occasionally, extensive retinal vessel closure will cause new, abnormal blood vessels to grow on the iris (colored part of the eye) and in the drainage channels in the front of the eye. This can block the normal flow of fluid out of the eye. Pressure in the eye builds up, resulting in **neovascular glaucoma**, a severe eye disease that causes damage to the optic nerve.

### HOW IS DIABETIC RETINOPATHY DIAGNOSED?

A medical eye examination is the best way to detect changes inside your eye.

An ophthalmologist (Eye M.D.) can often diagnose and treat serious retinopathy before you are aware of any vision problems. The ophthalmologist dilates (enlarges) your pupil and looks inside of the eye with special equipment and lenses.

If your ophthalmologist finds diabetic retinopathy, he or she may order color photographs of the retina or a special test called **fluorescein angiography** to find out if you need treatment. In this test a dye is injected into your arm and photos of your eye are taken to detect where fluid is leaking.

### HOW IS DIABETIC RETINOPATHY TREATED?

The best treatment is to prevent the development of retinopathy as much as possible. Strict control of your blood sugar will significantly reduce the long-term risk of vision loss from diabetic retinopathy. If high blood pressure and kidney problems are present, they need to be treated.

**Medical treatment.** Injections of anti-VEGF medication in the eye can stop the growth of new blood vessels and subsequent bleeding. VEGF is necessary for the eye to build new blood vessels and the use of anti-VEGF medication causes regression of these fragile and abnormal blood vessels. Sometimes a steroid medication may also be used.

**Laser surgery.** Laser surgery is often recommended for people with macular edema, PDR and neovascular glaucoma.

For macular edema, the laser is focused on the damaged retina near the macula to decrease the fluid leakage. The main goal of treatment is to prevent further loss of vision. It is uncommon for people who have blurred vision from macular edema to recover normal vision, although some may experience partial improvement. A few people may see the laser spots near the center of their vision following treatment. The spots usually fade with time but may not disappear.

For PDR, the laser is focused on all parts of the retina except the macula. This **panretinal photocoagulation** treatment causes abnormal new vessels to shrink and often prevents them from growing in the future. It also decreases the chance that vitreous bleeding or retinal distortion will occur.

Multiple laser treatments over time are sometimes necessary. Laser surgery does not cure diabetic retinopathy and does not always prevent further loss of vision.

**Vitrectomy.** In advanced PDR, your ophthalmologist may recommend a vitrectomy. During this microsurgical procedure, which is performed in the operating room, the blood-filled vitreous is removed and replaced with a clear solution. Your ophthalmologist may wait for several months to see if the blood clears on its own before performing a vitrectomy.

Vitrectomy often prevents further bleeding by removing the abnormal vessels that caused the bleeding. If the retina is detached, it can be repaired during the vitrectomy surgery. Surgery should usually be done early because macular distortion or traction retinal detachment will cause permanent visual loss. The longer the macula is distorted or out of place, the more serious the vision loss will be.

## VISION LOSS IS LARGELY PREVENTABLE

If you have diabetes, it is important to know that today, with improved methods of diagnosis and treatment, a smaller percentage of people who develop retinopathy have serious vision problems. Early detection of diabetic retinopathy is the best protection against loss of vision.

You can significantly lower your risk of vision loss by maintaining strict control of your blood sugar and blood pressure, and by visiting your ophthalmologist regularly.

## WHEN TO SCHEDULE AN EXAMINATION

People with Type 1 diabetes should schedule an examination within five years of being diagnosed and then yearly. People with Type 2 diabetes should have an exam at the time of diabetes diagnosis and then once a year.

Pregnant women with diabetes should schedule an appointment in the first trimester because retinopathy can progress quickly during pregnancy.

If you need to be examined for eyeglasses, it is important that your blood sugar be consistently under control for several days when you see your ophthalmologist. Eyeglasses that work well when blood sugar is out of control will not work well when blood sugar is stable.

Rapid changes in blood sugar can cause fluctuating vision in both eyes, even if retinopathy is not present.

You should have your eyes checked promptly if you have visual changes that:

- Affect either one or both eyes;
- Last more than a few days;
- Are not associated with a change in blood sugar.

When you are first diagnosed with diabetes, you should have your eyes checked:

- Within five years of the diagnosis if you are 29 years old or younger;
- Within a few months of the diagnosis if you are 30 years old or older.

### COMPLIMENTS OF:

### Academy reviewed 09/11

© 2011 American Academy of Ophthalmology. The American Academy of Ophthalmology, The Eye M.D. Association and the Academy logo are registered trademarks of the American Academy of Ophthalmology.